



## ILAE Surgical Mentorship Program

Ulaanbaatar, Mongolia, July 06-10, 2025

### Mentors

Prof. Kensuke Kawai, Department of Neurosurgery, Jichi Medical University

Prof. Naoto Kunii, Department of Neurosurgery, Jichi Medical University

Prof. Hideaki Shiraishi, Department of Pediatrics, Dokkyo Medical University

### Local faculty:

Prof. Tovuudorj Avirmed, Department of Neurology and Neurosurgery, Epilepsy center, Mongolia-Japan hospital, Mongolian National University of Medical Sciences

Dr. Enkhbold Dorjgotov, Neurosurgeon

Dr. Altan-Ochir Sanjdorj, Neurosurgeon

Dr. Tseren-Ochir Batbayar, Neurosurgeon

Dr. Gansuud Oidovdorj, Neurologist

Dr. Mendjargal Naranbat, Neurologist

Dr. Solongo Tsogt, Neurologist

Dr. Budlkhani Jamiyan, Neurologist

Dr. Amarsanaa Lkhagvasuren, Neurologist

Dr. Enkhjargal Manjiilaa, Neurologist

### Phase 1: Virtual Case Discussions and Pre-Surgical Evaluation in Preparation for Epilepsy Surgery in Mongolia

As part of the ILAE Local Mentorship Program, the Mongolian epilepsy care team participated in a structured series of virtual case discussions and pre-surgical evaluations, guided by expert mentors from Japan—Prof. Kensuke Kawai, Prof. Naoto Kunii (Department of Neurosurgery, Jichi Medical University), and Prof. Hideaki Shiraishi (Department of Pediatrics, Dokkyo Medical University). Between January and July 2025, a total of five virtual meetings were conducted. During these sessions, 17 patients with drug-resistant epilepsy were reviewed in detail, with a focus on diagnostic interpretation, imaging analysis, and surgical candidacy assessment.

This collaborative process significantly strengthened the Mongolian team's clinical expertise in epilepsy surgery, improved multidisciplinary coordination, and enhanced their readiness to begin local surgical interventions for drug-resistant epilepsy.

Table 1. Epilepsy patients discussed during online meetings (January to July, 2025)

	No	Age/Sex	Onset	Cause	Seizure type	EEG findings	MRI findings	Discussion/ Diagnosis	WMS-IV
<b>January 15, 2025</b>	1	44y, f	16 y	Unknown	Aura+ FIAS FBTCS	2 seizure- FIAS  F7-T3	Mesial temporal lobe atrophy at the left side	Left anterior temporal lobectomy	
	2	14y, m	4 y	Unknown	head drops, brief tonic seizure	GSW, GSSW followed by voltage attenuation	Thickened cortex with reduced secondary sulci in the bilateral frontal lobes: pachygyria Gr IV	DS: LGS Corpus callosotomy	
<b>February 20, 2025</b>	3	48y, f	41 y	Cavernoma	FAS: FIAS: FBTCS:	2 seizure- FIAS  F8-T4	Cavernoma in the right temporal lobe (zabramski type 2)	Resection	
	4	14y, f	8y	Febrile seizure	Aura (fear) +, FIAS +, FBGTC -	3 seizure- FIAS  F7-T3	Volume loss in the left hippocampus: mesial temporal sclerosis	Left anterior temporal lobectomy	
<b>April 01, 2025</b>	5	37 y, m	6 y	Febrile seizure	FAS FIAS FBTCS	2 seizure- FIAS  F7-T3	2024/12/16 Small left hippocampus with decreased inner layer differentiation: atrophy, moderate	<b>Surgery candidate</b> DS: Left TLE Anterior temporal lobectomy	Right handedness AMI-94 VMI-65 VWMI-94 IMI-77 DMI-80
	6	32y, f	24 y	Unknown	Aura FAS FIAS	1 seizure- FIAS  F7-T3	2025/02/27 Left mesial temporal sclerosis	<b>Surgery candidate</b> DS: Left TLE -ECoG -Selective SAH?	Left handedness AMI-144 VMI-119 VWMI-136 IMI-133 DMI-137
	7	22 y, f	17 y	Febrile seizure	Aura FAS FIAS FBTCS	2 seizure- FBTCS  F8-T4	2025/03/26 Bilateral smaller hippocampus with T2/FLAIR hypertensity (more on the right side) DDx bilateral mesial temporal sclerosis	<b>(later list, on July) Surgery candidate</b> DS: Right TLE  -Intracranial EEG	Right handedness AMI-84 VMI-62 VWMI-85 IMI-69 DMI-72
	8	32 y, f	25 y	Unknown	Aura FIAS FBTCS	2 seizure- FIAS  F7-T3	2024/12/30 Volume decrease in the left hippocampus: mild atrophy	<b>Surgery candidate</b> DS: Left TLE -Transection? (mild atrophy)	Right handedness AMI-95 VMI-73 VWMI-73 IMI-86 DMI-78
<b>May 05, 2025</b>	9	44 y, m	20 y	Suspected meningitis	Aura FIAS FBTCS	2 seizure- not clear  F8-T4	2024/07/28 Mesial temporal sclerosis in right side	<b>Surgery candidate</b> DS: Right TLE Even ictal seizure is not clear he is surgery candidate	
	10	26 y, m	5 y	Febrile seizure, Traumatic injury due to FIAS	FIAS FBTCS	2 seizure- Figure 4 sign?	2025/03/10 1.Gliotic encephalomacia in the right frontal-parietal, temporal and left frontal lobes 2.Left hippocampal atrophy	Re-evaluate the semiology of seizure, ictal EEG	
	11	42 y, f	10 y	Unknown	Aura FIAS-undress	6 seizures FIAS All F7-T3	2025/04/23 MRI negative	-Wada test - SEEG	

June 19, 2025	12	32 y, m	19 y	Anemia-6 months	FIAS- face wiping FBTCS	3 seizure- 1FIAS+GTC 2FIAS  F7-T3	2024/09/25 Significance thinner left hippocampus than right side	DS: Frontal lobe epilepsy (Orbitofrontal cortex origin?) Intracranial EEG	
	13	38y, f	12 y	Febrile seizure	Aura FIAS FBTCS	2 seizure FIAS , GTC (Figure of 4?) F7-T3	2025/04/24 Left mesial temporal sclerosis	<b>Surgery candidate</b> DS: Left TLE	Right handedness AMI-72 IMI-60 VMI-55 DMI-61 VWMI-56
	14	32 y, female	28 y	Febrile seizure	Aura FAS FIAS	1 seizure- FIAS  F7-T3	2025/05/26 Calvarial deformity with right side being short: suggestive of anterior synostotic plagiocephaly	- MRI negative - Intracranial EEG	
	15	39 y, female	21 y	Meningitis Tuberculosis	Aura FIAS FBTCS	2 seizure- FIAS  F8-T4	2023/11/08 - Multifocal calcified round lesions in the brain (S/O Calcified TB granulomas. DDx neurocysticercosis, other CNS infections and metastasis etc.) - Right mesial temporal sclerosis (right hippocampus atrophy)	<b>Surgery candidate</b> DS: Right TLE  TB- confirm	
	16	44 y, male	20 y	Suspected meningitis	Aura FIAS FBTCS	2 seizure- FIAS  F8-T4	2024/07/28 Mesial temporal sclerosis in right side	<b>Surgery candidate</b> DS: Right TLE	Right handedness AMI-47 VMI-46 VWMI-60 IMI-42 DMI-46
	17	42 y, female	10 y	Unknown	Aura FIAS-undress	6 seizures FIAS All F7-T3	2025/04/23 MRI negative	DS: Right TLE? -MRI negative - Intracranial EEG	

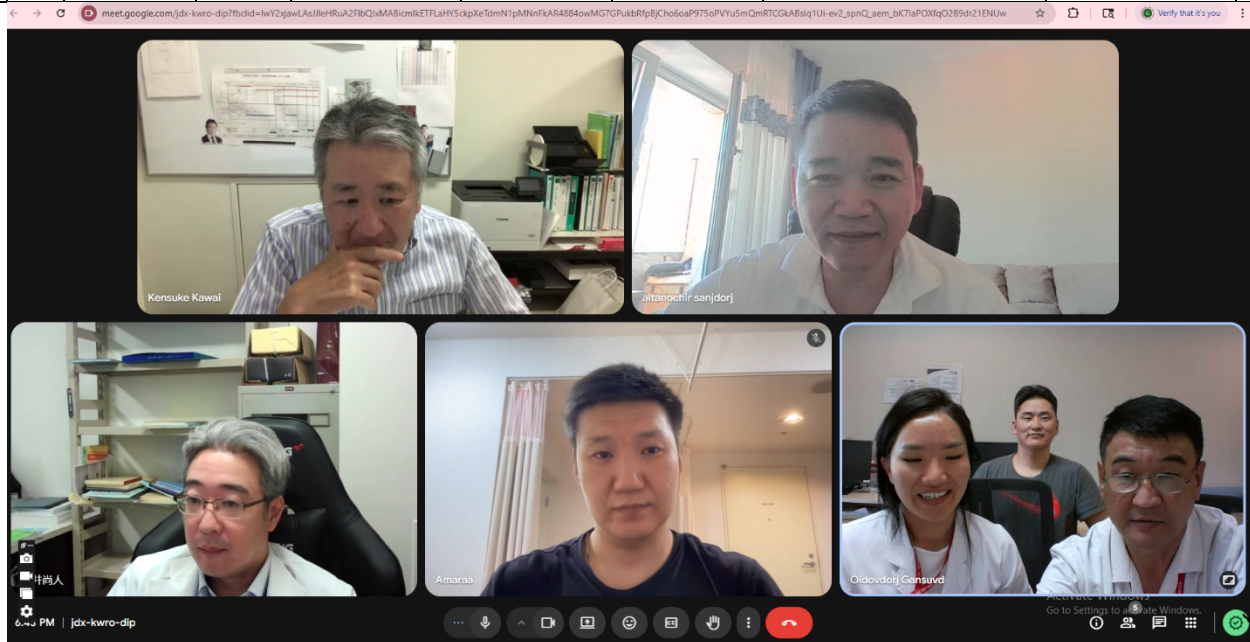

Figure 1. Online case discussion

## Phase 2: ILAE Round 1 – July 6–10, 2025

ILAE Round 1 took place from July 6 to July 10, 2025, at the Epilepsy Center, Mongolia-Japan Hospital in Ulaanbaatar, Mongolia, as part of the ILAE Local Mentorship Program.

During this visit, a total of six epilepsy surgeries were successfully performed—two per day from July 7 to July 9—with Prof. Kensuke Kawai and Prof. Naoto Kunii.

In parallel with the surgical program, academic and clinical activities were organized to support local capacity building:

- On July 7, a symposium was held for local physicians and healthcare professionals, covering topics such as epilepsy surgery indications, multidisciplinary evaluation, case selection and pediatric epilepsy
- On July 8, the team guided by Prof. Hideaki Shiraishi conducted patient consultations and information sessions, offering comprehensive guidance to individuals with drug-resistant epilepsy and their families regarding surgical options and the pre-surgical workup process.

This integrated approach—combining surgery, professional education, and direct patient care marked a significant step toward establishing a sustainable and advanced epilepsy surgery program at the Mongolia-Japan Hospital.



Figure 2. “Experiences and advances in epilepsy surgery” workshop/symposium

**"EXPERIENCE AND ADVANCES IN EPILEPSY SURGERY"****SYMPOSIUM / WORKSHOP**

<b>Day 1, July 7, Monday</b>		
8.00-8.30	Registration	
8.30-9.00	Opening Ceremony	Prof.Tovuudorj.A MD,PhD Head of the Department of Neurology, MNUMS Prof.Kensuke Kawai MD,PhD Director of the Jichi Medical University Hospital, Japan
<b>Section 1</b>		
		<i>Coordinator:Prof.Tovuudorj.A MD,PhD Chairman :Tungalagtamir.Sh MD, PhD</i>
Time	Symposium Topic	Speaker
09.00-09.15	Activities of Epilepsy Center of MJH	Prof.Tovuudorj.A MD, PhD
09.15-09.30	<b>Epilepsy Surgery Treatment and Outcomes</b>	<b>Prof.Kensuke Kawai MD, PhD</b>
09:30-10.10	<b>Epileptic syndrome Overview</b>	<b>Prof.Hideaki Shiraishi MD, PhD</b>
10.10-10.30	Brain Abnormalities in Children with Epilepsy Studied Using MRI	Delgerdalai.Kh MD, PhD (Department of Radiology, MNUMS)
10.30-11.00	Non epileptic paroxysmal events	Mendjargal.N MD, McS (Department of Neurology, MNUMS)
11.00-11.10	Pharmaceutical company	
11.10-11.20	Coffee Break	
11.20-12.00	<b>Pediatric Epilepsy: Treatment and management</b>	<b>Prof.Hideaki Shiraishi MD, PhD</b>
12:00-13:00	LUNCH	
<b>Workshop</b>		
13.00-14.30	Pediatric epilepsy, Semiology and EEG	Mentor: Prof.Hideaki Shiraishi Gansuvd.O MD, McS Solongo Ts, MD Mendjargal N, MD
14:30-16:30	Case discussion with small group (Epileptologist, Residency)	

<b>Day 2, July 08, Tuesday</b>		
<b>PATIENT'S FAMILY AND PUBLIC EDUCATION programme</b>		
Time	Symposium Topic	Speaker
13:30-13:50	Classification of epilepsy and epilepsy syndrome	Gansuvd O
13:50-14:10	General concepts of drug-resistant epilepsy	Hideaki Shiraishi MD, PhD
14:10-14:30	Principles of pharmacological treatment	Hideaki Shiraishi MD, PhD
14:30-15:00	<b>Interdisciplinary discussions with patients and their families</b> Answer and question	Hideaki Shiraishi MD, PhD
15:00	Closing remarks	Prof. Kensuke Kawai Hideaki Shiraishi MD, PhD



Figure 3. “Experiences and advances in epilepsy surgery” workshop/symposium



Figure 4. Prof. Kensuke Kawai presenting during the symposium

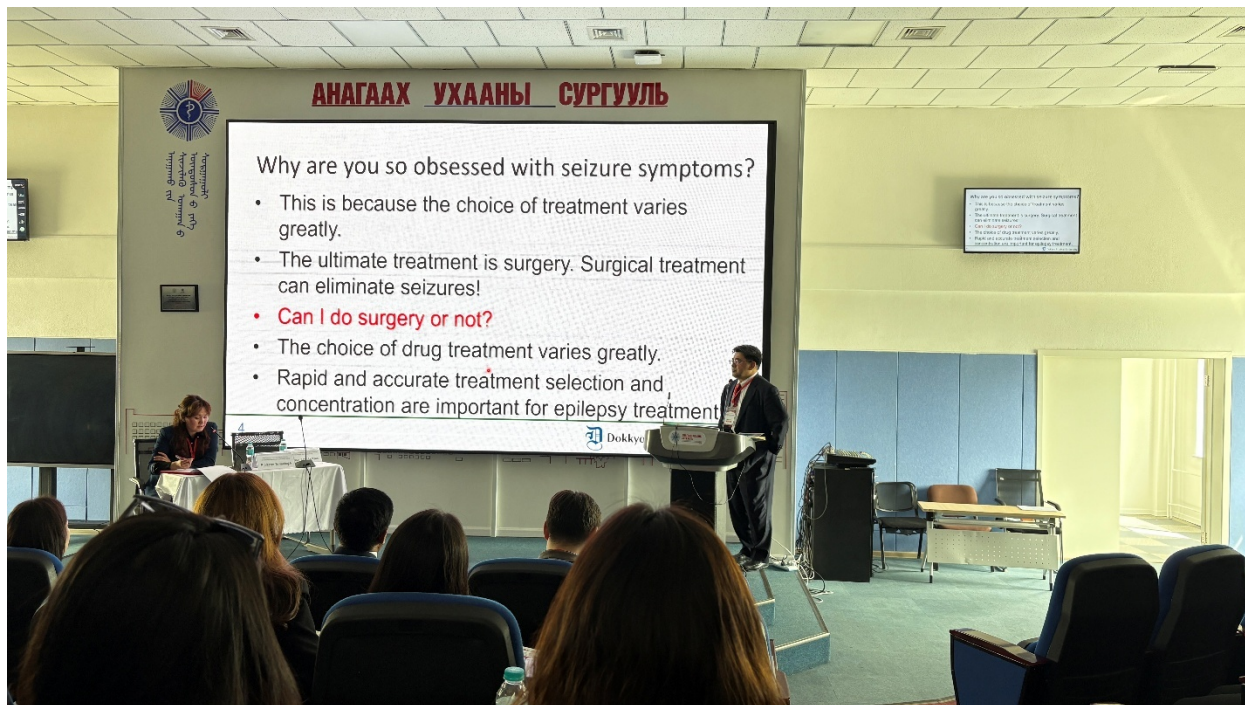

Figure 5. Prof. Hideaki Shiraishi presenting during the symposium



Figure 6. Day-2 Prof. Hideaki Shiraishi presenting during the public education sessions for patients and their families



Figure 7. Day 2 – Prof. Kensuke Kawai introducing the concept of epilepsy surgery during a public education session with patients and their families.



Figure 8. Day-2 Prof. Hideaki Shiraishi engaging in case discussions with neurologists and providing recommendations for patients and their families

### Phase 3: PATIENT PREPARATION FOR SURGERY

After the visit, clinical case discussions continued and became increasingly productive. Through these detailed case reviews and a thorough assessment of the surgical team's capabilities, six patients were carefully selected to undergo surgery.

Table 2. List of patients who underwent surgery

Nº	Age/Sex	Onset	Cause	Seizure type	EEG findings	MRI findings	Surgery	WMS-IV
1	37 y, m	6 y	Febrile seizure	FAS FIAS FBTCS	2 seizure- FIAS  F7-T3	2024/12/16 Small left hippocampus with decreased inner layer differentiation: atrophy, moderate	Left TLE Anterior temporal lobectomy	Right handedness AMI-94 VMI-65 VWMI-94 IMI-77 DMI-80
2	32y, f	24 y	Unknown	Aura FAS FIAS	1 seizure- FIAS  F7-T3	2025/02/27 Left mesial temporal sclerosis	Left TLE Anterior temporal lobectomy	Left handedness AMI-144 VMI-119 VWMI-136 IMI-133 DMI-137
3	32 y, f	25 y	Unknown	Aura FIAS FBTCS	2 seizure- FIAS  F7-T3	2024/12/30 Volume decrease in the left hippocampus: mild atrophy	Left TLE Anterior temporal lobectomy	Right handedness AMI-95 VMI-73 VWMI-73 IMI-86 DMI-78
4	38y, f	12 y	Febrile seizure	Aura FIAS FBTCS	2 seizure FIAS , GTC (Figure of 4?) F7-T3	2025/04/24 Left mesial temporal sclerosis	Left TLE Anterior temporal lobectomy	Right handedness AMI-72 IMI-60 VMI-55 DMI-61 VWMI-56
5	39 y, f	21 y	Meningitis Tuberculosis	Aura FIAS FBTCS	2 seizure- FIAS  F8-T4	2023/11/08 - Multifocal calcified round lesions in the brain (S/O Calcified TB granulomas. DDx neurocysticercosis, other CNS infections and metastasis etc.) - Right mesial temporal sclerosis (right hippocampus atrophy)	Right TLE Anterior temporal lobectomy	Right handedness AMI-84 VMI-105 VWMI-83 IMI-94 DMI-93
6	44 y, m	20 y	Suspected meningitis	Aura FIAS FBTCS	2 seizure- FIAS  F8-T4	2024/07/28 Mesial temporal sclerosis in right side	Right TLE Anterior temporal lobectomy	Right handedness AMI-47 VMI-46 VWMI-60 IMI-42 DMI-46

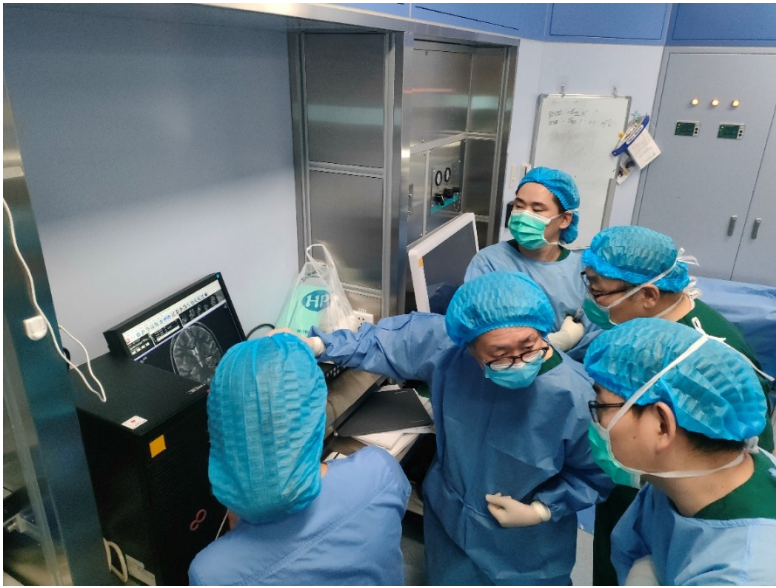
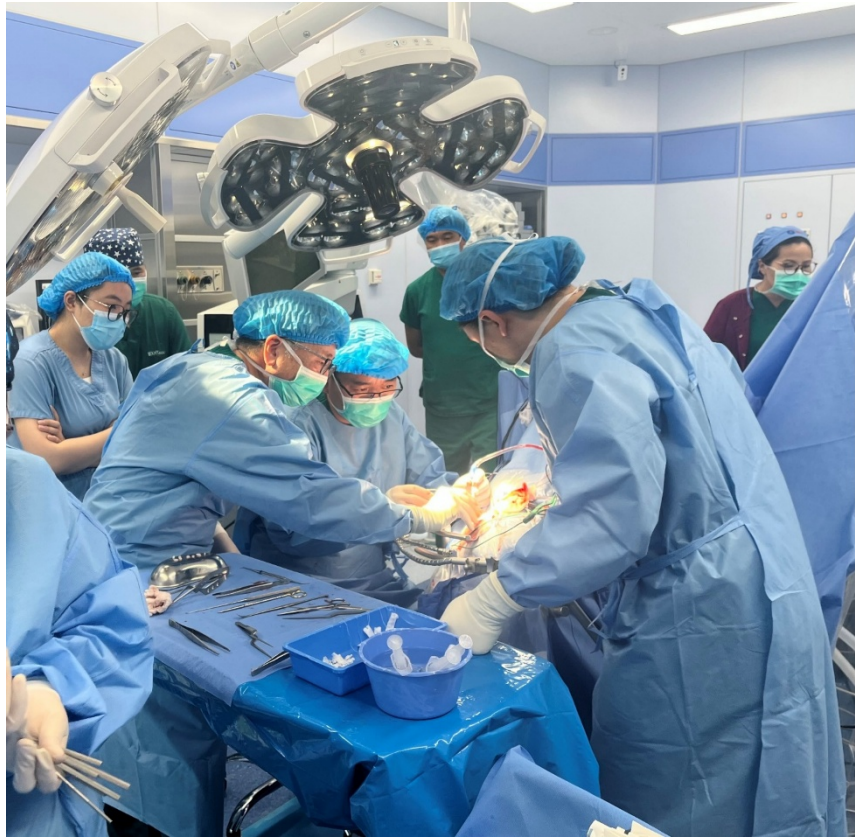
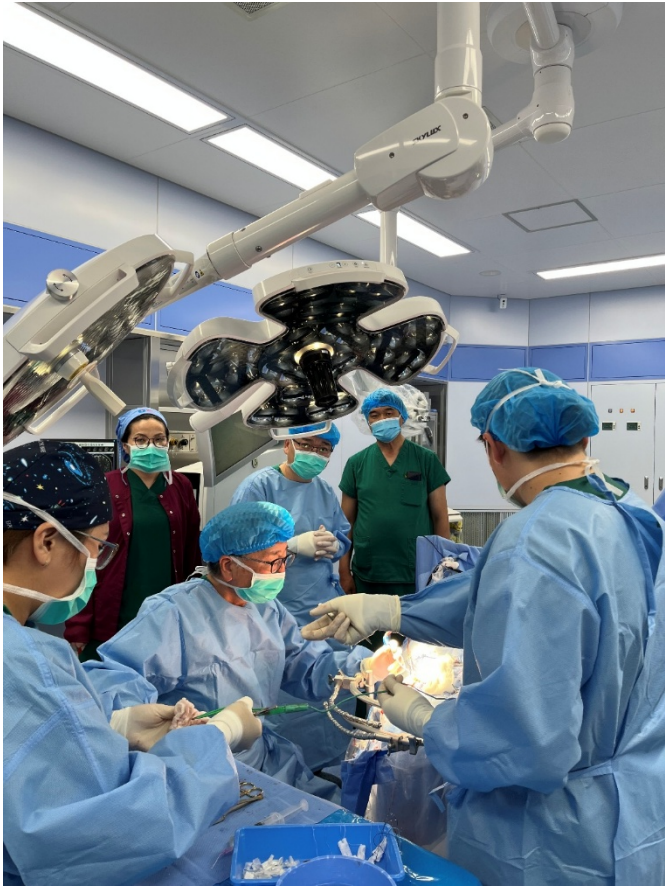Figure 9. Prof. Kensuke Kawai mentoring the surgical team during the epilepsy surgery

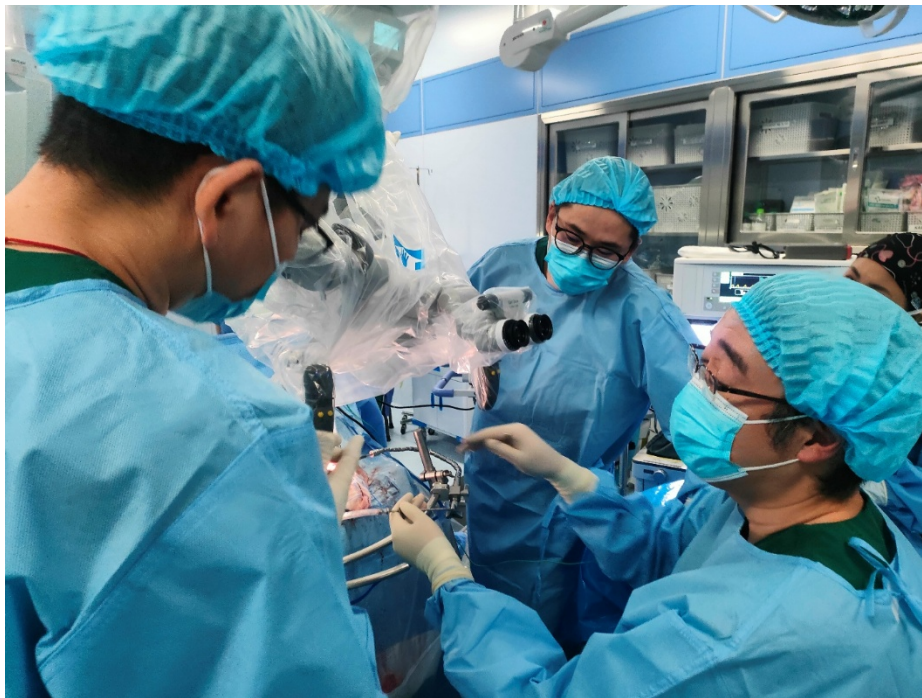
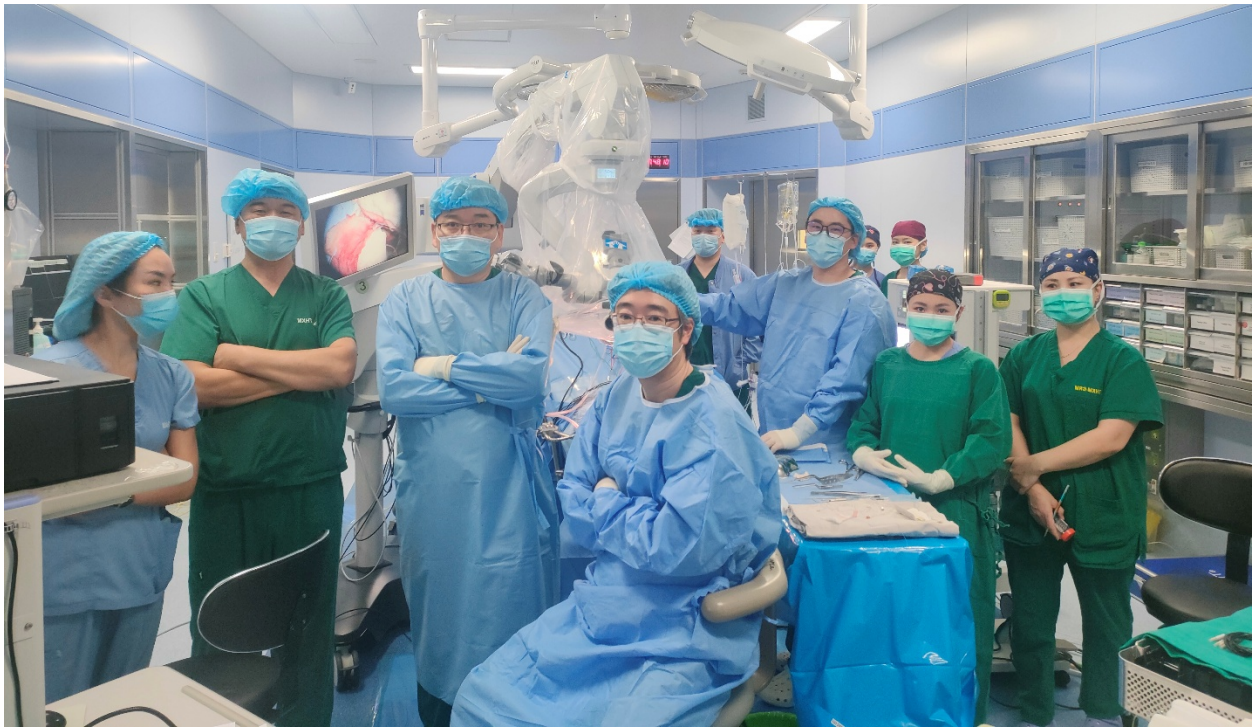
Figure 10. Prof.Naoto Kunii mentoring the surgical team during the epilepsy surgery

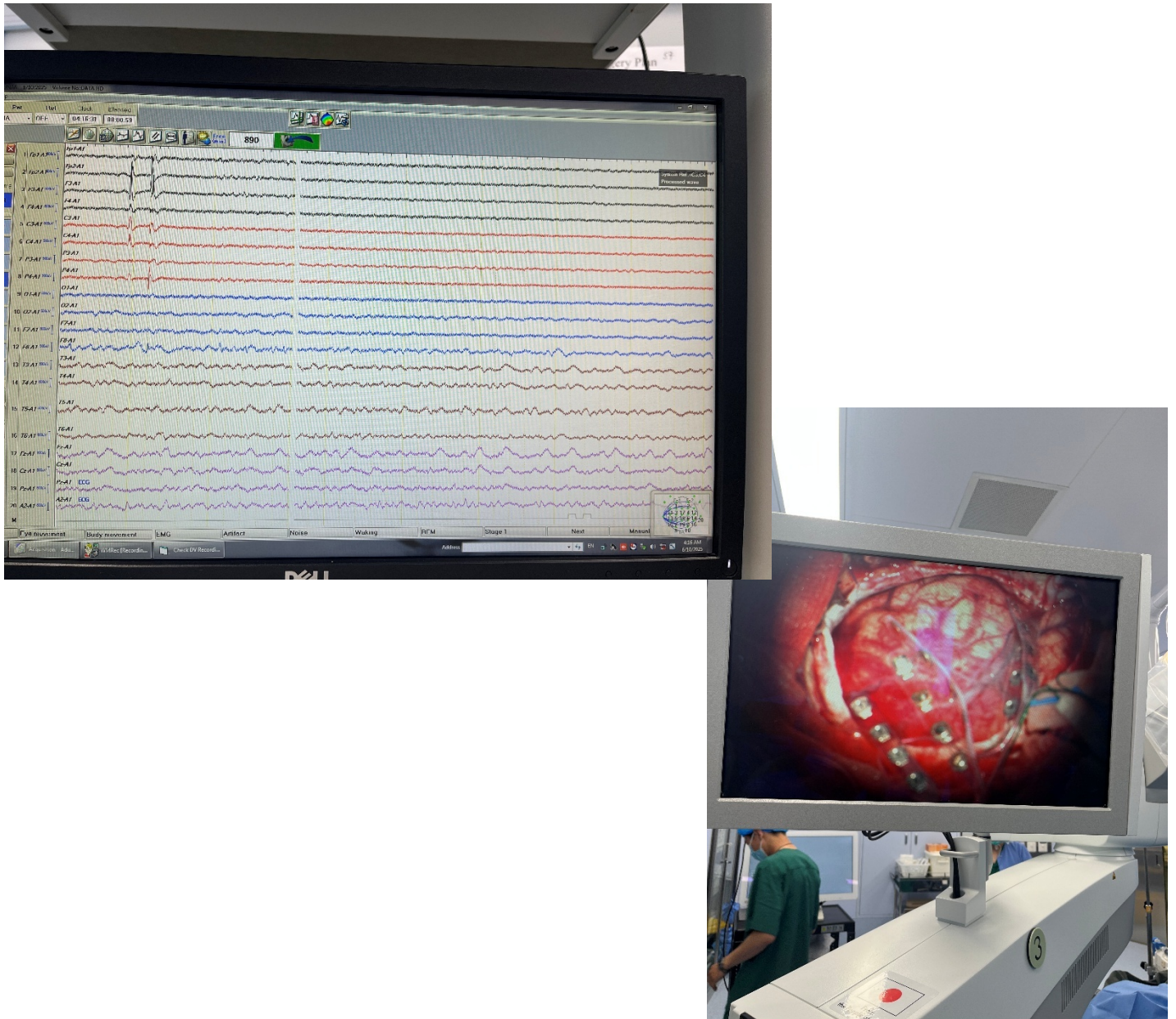


Figure 11. Intraoperative use of electrocorticography (ECoG) during epilepsy surgery.

Six patients underwent anterior temporal lobectomy, during which intraoperative ECoG (electrocorticography) was utilized. The surgical team was trained on how to effectively apply ECoG during the procedures and its importance for future surgeries.

To support the implementation of the program, the mentors held a meeting with the Director of the Mongolia-Japan Hospital. The Director expressed full support for the initiative and emphasized the hospital administration's willingness to assist in securing essential equipment and human resources. Future collaboration with the Departments of Neurology and Neurosurgery was also discussed, with a focus on the sustainable development of epilepsy surgery services.



Figure 12. Meeting with Director of Mongolia-Japan hospital



Figure 13 Meeting with Department of Neurology and Neurosurgery, School of Medicine, Mongolian National University of Medical Sciences

We would like to express our sincere gratitude to the Japanese professors for visiting our center. After three days of intensive clinical collaboration, the team shared a moment of relaxation with a group dinner and a visit to Terej National Park—strengthening professional ties and celebrating international cooperation.



Figure 14. Dinner with team in Terej National Park



Figure 15. Team photo in front of the Mongolia-Japan Hospital, Ulaanbaatar.



Figure 16. Group photo at the hospital following the meeting with Their Majesties

During our program, we had the honorable opportunity to welcome Their Majesties Emperor Naruhito and Empress Masako of Japan to the Mongolia-Japan Hospital. Their Majesties personally met with our team and were introduced to our ongoing activities—a truly memorable and significant moment for all involved.

### ACKNOWLEDGMENTS

The visit of **Prof. Kensuke Kawai** and his esteemed colleagues marked a milestone in the advancement of epilepsy care in Mongolia. Their mentorship was not only informative, but also transformative—demonstrating how comprehensive presurgical evaluations can be effectively carried out using our existing local resources.

Throughout their visit, they introduced a range of surgical techniques, while consistently emphasizing the importance of integrating clinical, electrophysiological, and neuroimaging data for precise diagnosis and optimal surgical outcomes. Their hands-on guidance empowered our team to move closer toward establishing a sustainable epilepsy surgery program.

We are profoundly grateful to **Prof. Kensuke Kawai**, **Prof. Naoto Kunii**, and **Prof. Hideaki Shiraishi** for their outstanding support, expertise, and dedication. Their visit not only enhanced our professional capacity, but also inspired a stronger vision for the future of epilepsy care in Mongolia. Their contributions will have a lasting impact, and they will always be remembered as true mentors and respected representatives of the **International League Against Epilepsy (ILAE)**